POST-TRAUMATIC ANTERIOR SKULL BASE DEFECT IN A PAEDIATRIC PATIENT

D'Aleo Canova Giulia, MD[1,2], Francesca De Bernardi MD[1,3], Maurizio Bignami, MD[1,2,3], Paolo Castelnuovo[1,3], Paolo Battaglia[1,3]

[1]Division of Otorhinolaryngology, Department of Biotechnology and Life Sciences, University of Insubria, Varese, Italy.
[2] Department of Otorhinolaryngology, ASST Lariana, Como, Italy
[3]Head and Neck Surgery & Forensic Dissection Research Center (HNS&FDRc), Department of Biotechnology and Life Sciences, University of Insubria, Varese, Italy.

CORRESPONDING AUTHOR:
D'Aleo Canova Giulia, MD
Division of Otorhinolaryngology, Department of Biotechnology and Life Sciences, University of Insubria, Ospedale di Circolo e Fondazione Macchi, Via Guicciardini 9, 21100, Varese, Italy.
Phone: (+39) 3881766251 - Fax: (+39) 3881766251 E-mail: giulia.daleocan@gmail.com

ABSTRACT

Cerebrospinal fluid (CSF) leaks are rare conditions that can mainly be divided into two categories: traumatic and spontaneous. They can be associated with a significant morbidity mostly defined by intracranial complications, which is why a timely diagnosis is essential as to locate and assess the extent of the damage. Their management can be medical or surgical, based on the nature, the location, and the size of the leak. We present to you the case of a 3-year-old girl involved in a car accident resulting in head trauma for which she was admitted to the emergency room (ER). Radiological assessments showed multiple bilateral displaced fractures of the fronto-ethmoidal skull base and a suspect of meningocele was also reported. Due to the age of the patient, the radiological evidence of an anterior skull base defect and given the risk of complications related to an intracranial approach, the surgical team decided to proceed with a skull-base reconstructive surgery through an endoscopic endonasal approach.

A) INTRODUCTION

Post-traumatic anterior skull base defects, resulting in cerebrospinal fluid (CSF) leaks, present a lower incidence in children than in adults, occurring in 0.2-0.3% of paediatric head trauma[1]. The leak of CSF results from an anomalous communication between the subarachnoid space of the anterior skull base and the underlying nasal cavities. The clinical manifestations of post-traumatic anterior skull base defects can vary from totally asymptomatic, to causing intermittent rhino liquorrhea or recurrent episodes of meningitis. A CSF-leak could also be complicated by the presence of meningoceles or encephaloceles, therefore increasing the risk of meningitis, intracranial abscess, and pneumo encephalon. A timely diagnosis, through ENT and/or neurosurgical evaluation plus radiological assessments such as Head CT-scan and MRI are essentials to define the localization and size of the defect, in order to decide on the most successful therapeutic strategy[2]. While it is common agreement that early surgical repair is the main tool to decrease the

incidence of ascending infections, skull base surgery in paediatric patients, which can be both open and endoscopic, entails a high risk of complications. Also, a wait and see strategy may be chosen in carefully selected cases, such as asymptomatic anterior skull base defect without any major complications displaying a higher chance of spontaneous resolution.

B) CASE REPORT

A 3-year-old girl was involved in a car accident resulting in head trauma. She was therefore taken to the emergency room and underwent an urgent head and brain CT scan showing a bilateral displaced fracture of the fronto-ethmoidal skull base (Figure 1). Head MRI was also performed, being very helpful to detect CSF leaks or meningoceles, especially using a method that consists in merging a FLAIR-sequence, that suppresses the cerebrospinal fluid, with a T2-weighted sequence, which, on the opposite, highlights all liquid elements. The fusion sequence resulting from this union highlights specifically the cerebrospinal fluid, allowing to better evaluate any CSF loss or herniation of the meninges. In this specific case, MRI showed a suspect of bilateral meningocele, greater on the left side (Figure 2). Therefore, despite the lack of apparent rhino-liquorrhea, due to the high suspect of meningocele, a surgical treatment was preferred to a wait-and-see strategy, to avoid ascending infections and intracranial complications. The surgical team decided to proceed with an endoscopic endonasal approach. To increase the chances of success of this surgery, the procedure should be preceded by an intrathecal injection of fluorescein (in this case using a 5% concentration and injecting 0.25 cc through a lumbar puncture). The use of this substance in the treatment of CSF-leaks is still off-label but has shown to be both safe and effective if used in low doses[6]. The first step of the endoscopic endonasal surgery of the anterior skull base is to expand the manoeuvring space to improve the visibility of the anatomical area of interest. To reach this goal we performed a bilateral middle meatal antrostomy, removed both ethmoidal boxes and the bony portions of the middle turbinates, leaving the medial mucosa of both turbinates for the subsequent skull base reconstruction. We removed residual bone spicules from the anterior skull base until any loss of fluorescein or herniation of the meninges was highlighted. Once the anterior skull base was completely exposed, a leak of fluorescein was clearly observable on the left side, coming from a bony fracture on the most anterior portion of the fronto-ethmoidal skull base (Figure 3). In the light of this unilateral finding, we decided to proceed on the left side with a stratified skull base reconstruction with fascia lata taken from the right thigh, abdominal fat (Figure 4) and a last layer using the mucosa of the residual middle turbinate. Once the layer had all been stabilised and reinforced with fibrin glue, there were no more signs of fluorescein leak (Figure 5). The other nasal fossa, that didn't show signs of cerebrospinal fluid leak, was still treated with a reinforcement of the anterior skull base, using solely the mucosa of the residual middle turbinate. The procedure was considered completed, with a satisfactory result, once there were no other traces of fluorescein. The little patient was then transferred to the paediatric intensive care, received intravenous antibiotics and was kept under sedative medications for the first postoperative days to avoid any increases in intracranial pressure or physical movements that could hinder the healing process or even cause a disruption of the skull base plasty. On the second postoperative day, still under sedation, nasal tampons were removed, and the patient underwent the first post-operative

head CT-scan (Figure 6) that did not display any signs of pneumo encephalon, intracranial complications or discontinuity of the anterior skull base. After about a week in intensive care, the little patient was awakened and stayed another few days in the paediatric ward, with a progressive but controlled mobilisation from supine, to sitting and finally standing. No complications of an infectious or haemorrhagic nature appeared during the post-operative course, and the patient was therefore dismissed in good general conditions. During the post-operative follow-up, the little patient underwent regular outpatient check-ups and endoscopic endonasal dressings under sedation, every two weeks for the first two months, and then once a month until complete scarring of the mucosa without any signs of complications or recurrence of CSF-leak.

C) DISCUSSION

In our case, the choice regarding the surgical technique was hanging between open intracranial and endoscopic endonasal approach. While this decision is generally based on size and location of the leak, presence of meningocele, patient's general conditions and surgeon's preferences, the neurosurgical approach is usually preferred in large defects or comminuted fractures. However, in order to expose the anterior cranial bone, the surgeon must cut the olfactory tracts, leading to a high risk of anosmia. This surgical approach might also be complicated by pituitary and cavernous sinus wounds. On the other hand, the endoscopic endonasal approach, which has shown major progress over the last decade, allows the repair of an anterior skull base defect with a concomitant reduced risk of complications even in a paediatric population, as shown by Emanuelli et al. [4], and a success rate around 90%[2]. In addition, from a purely technical point of view, the endoscope allows a better view of the surgical field with greater precision since the camera can get much closer to the anatomical structures and is able to inspect even the most hidden areas, compared to the microscope used for the external approach.[5] In this specific case, even though the external technique through craniotomy would have normally been the first choice because of the extent of the skull-base defect and the suspect of meningocele, it represented an aggressive surgery with a high morbidity rate for a very young patient. Also, another big concern of performing an intracranial access on a three-year-old girl was the risk of post-operative anosmia. Therefore, in our case the endoscopic approach represented a safer choice while still being surgically adequate.

D) CONCLUSION

Endonasal endoscopic surgery is slowly becoming the gold standard in the treatment of anterior skull base CSF leaks in paediatric patients, as it is in adults, reducing morbidities and hospitalisation, while still proving a high success rate. However, since post traumatic anterior skull base CSF leak in paediatric patients are rare and delicate situations, it is difficult to carry out clinical studies in order to elaborate consensual algorithms for diagnosis and treatment. Therefore, the choice remains in the hands of the surgical team, based on their personal experience and skills.

REFERENCES

1. Ibrahim, A. A., Magdy, E. A. & Eid, M. Endoscopic endonasal multilayer repair of traumatic ethmoidal roof cerebrospinal

fluid rhinorrhea in children. *Int. J. Pediatr. Otorhinolaryngol.* 76, 523–529 (2012).

2. Galli, J., Morelli, F., Rigante, M. & Paludetti, G. Management of cerebrospinal fluid leak: the importance of multidisciplinary approach. *Acta Otorhinolaryngol. Ital.* 41, S18–S29 (2021).

3. Schoentgen, C., Henaux, P. L., Godey, B. & Jegoux, F. Management of post-traumatic cerebrospinal fluid (CSF) leak of anterior skull base: 10 years experience. *Acta Otolaryngol. (Stockh.)* 133, 944–950 (2013).

4. Emanuelli, E., Bossolesi, P., Borsetto, D. & D'Avella, E. Endoscopic repair of cerebrospinal fluid leak in paediatric patients. *Int. J. Pediatr. Otorhinolaryngol.* 78, 1898–1902 (2014).

5. Bedrosian, J. C., Anand, V. K. & Schwartz, T. H. The Endoscopic Endonasal Approach to Repair of Iatrogenic and Non Iatrogenic Cerebrospinal Fluid Leaks and Encephaloceles of the Anterior Cranial Fossa. *World Neurosurg.* 82, S86–S94 (2014).

6. Jolly, K., Gupta, K. K., Banota, A. & Ahmed, S. K. The Effectiveness and Safety of Intrathecal Fluorescein in the Management of Cerebrospinal Fluid Leaks. *Am. J. Rhinol. Allergy* 35, 879–884 (2021).

FIGURES

Figure 1

Preoperative head CT scan, on a sagittal section, showing a displaced fracture of the fronto-ethmoidal skull base

Figure 2

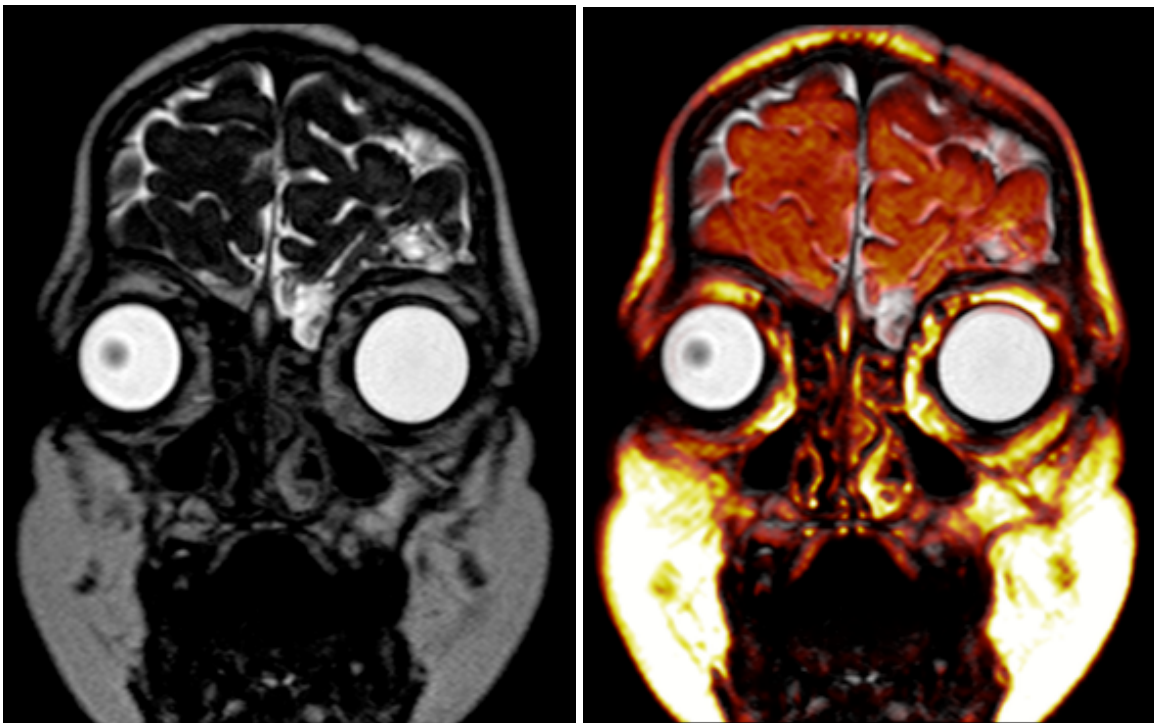

Preoperative head MRI scan, on a coronal section (Left: T2 weighted sequence, Right: Fusion sequence). On Fusion sequence, the accumulation of high intensity signal, depicting the cerebrospinal fluid, on the anterior portion of the roof of the left nasal fossa represents a suspect area for meningocele.

Figure 3

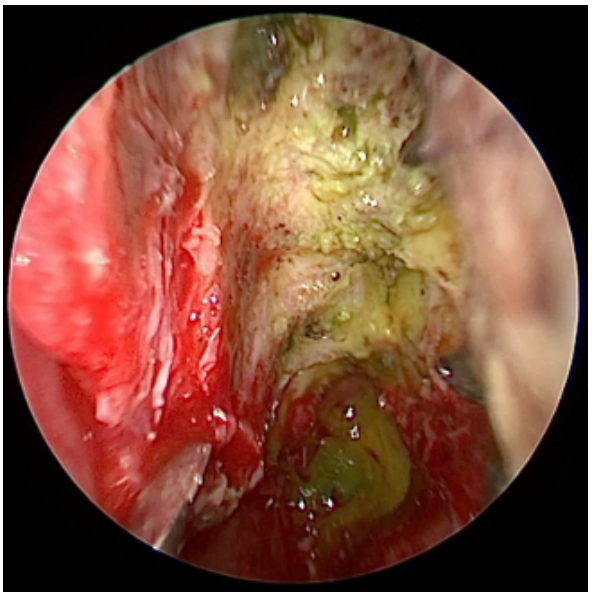

Intraoperative endoscopic view of the left nasal fossa: with the bony roof exposed, the fluorescein leak is clearly visible.

Figure 4

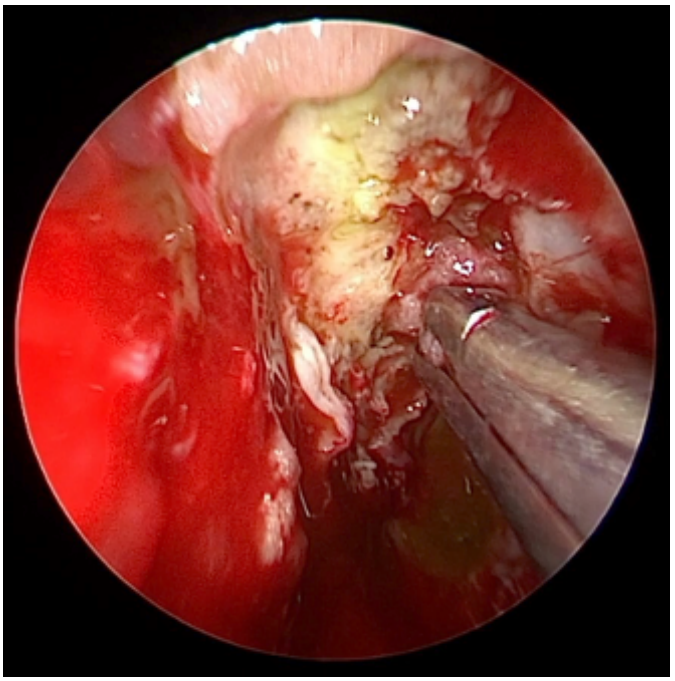

Intraoperative endoscopic view of the repairing process: the leak is progressively stopped by overlapping layers of fascia lata and abdominal fat.

Figure 5

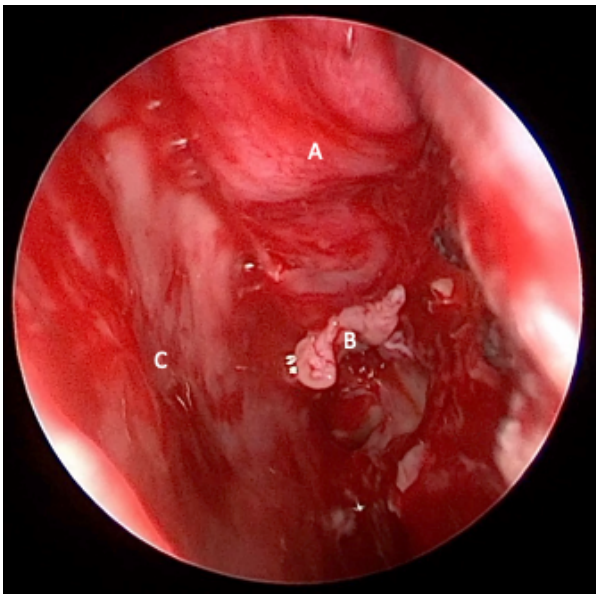

Intraoperative endoscopic view of the resulting skull base reconstruction on the lef nasal fossa: A. Mucosa of the middle turbinate folded towards the roof of the nasal cavity, B. Portion of fascia lata positioned to reinforce the posterior portion of the plasty, C. Nasal septum as reference.

Figure 6

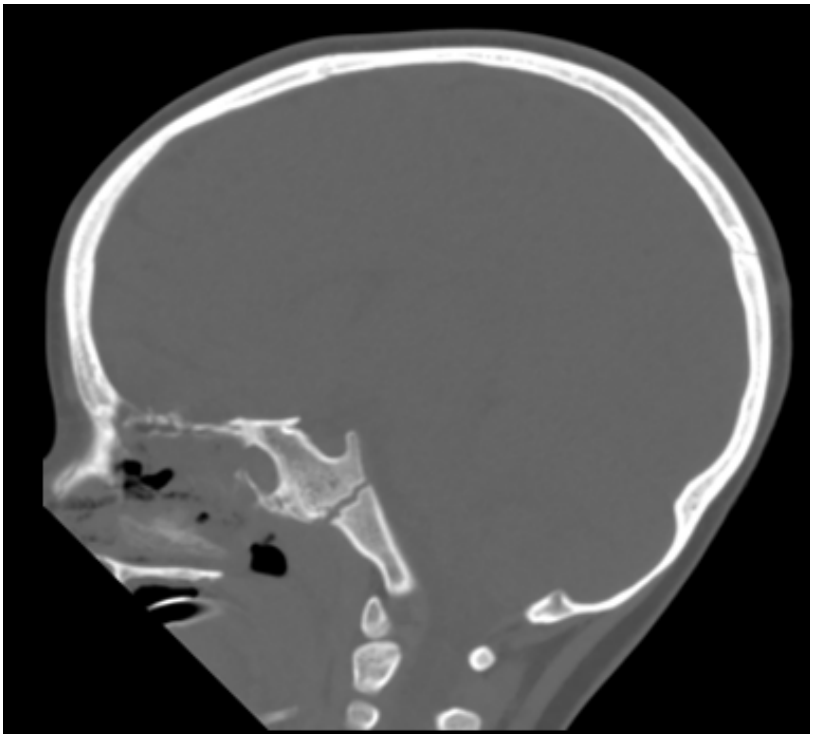

Post-operative head CT scan, on a sagittal section, performed 48 hours after surgery: no evidence of irregularities at the level of the anterior skull base, no signs of intracranial complications.