The Rhinologist

The Rhinologist 2.2018

ISSN 2531-9299

Italian Academy of Rhinology

Table of Contents

Editor: PSA&CF srl Via Procaccini, 24 21100 Varese

Registered in Varese Court at n. 5/2016

www.therhinologist.com

Editor in Varese
Four monthly Magazine

Varese, 1-7-2018

ISSN 2531-9299

ISSN 2531-9299

Certificato Qualità ISO 9001:2008
ICIM
Cert.N. 5232/0

THE RULE OF THREE IN PARANASAL SINUS MYCOSIS

Frank Rikki Canevari MD , Giorgio Peretti MD, Giacomo Sollini MD

Department of Otorhinolaryngology-Head and Neck Surgery, University of Genova,Italy

The diagnostic classification and treatment of fungal rhinosinusitis (FRS) is still challenging. The type of infection depends on the aggressiveness of the fungus and the patient's immune status. FRS is most commonly classified as noninvasive or invasive. The invasive forms are characterized by the presence of hyphae within the mucosa, submucosa, vessels and bone and can be divided into acute fulminant invasive, chronic invasive and granulomatosis invasive. Non-invasive forms are extra mucosal without deep invasion and are divided into fungus ball and allergic fungal sinusitis.[1,2]

The differentiation of the type of sino-nasal mycosis is crucial to the choice of the relevant treatment. Fungus ball require an exclusive endoscopic surgical approach aimed at restoring paranasal sinus ventilation as well as chronic invasive type need the association of surgery, tailored to the patient, and systemic pharmacological treatment. Even though every single type of mycosis has its typical clinical manifestation and radiological findings, in some cases, it would be hard to determine the true form of disease especially in the differentiation between fungus ball and chronic invasive mycosis. Especially for the invasive form, identification of the fungal agent responsible is necessary to guide therapy given the differing susceptibility profiles.

Since 2000 we have adopted a clinical habit in intraoperative diagnosis of paranasal sinus mycosis which has proven to be a useful rule. We called it "*the rule of three*". In surgical approach, when the affected paranasal sinus is reached, three samples are collected for three different laboratory examinations (Fig.1).

1) The first part of sinus material is sent for histological examination in order to demonstrate the presence of hyphae.
2) The second part is collected and sent to microbiological laboratory in order to define the type of hyphae involved
3) A biopsy of the mucosa is sent for histological examination in order to exclude submucosal and vessels invasion.

Clinical cases

In order to give a practical demonstration of the useful of the role of three we present three different cases of sphenoidal mycosis

Case 1: Female 61 years. High blood pressure controlled with medical therapy. The patient was affected by four-month occipital headache, right retro orbital pain, right nasal obstruction e posterior rhinorrea. The endoscopic examination showed an oedema of sphenoethmoidal recess with discharge of thick mucus from the posterior paranasal sinus compartment. When the patient was referred to ENT specialist had already done two therapies with oral antibiotics and nasal steroid without any improvement of the symptoms.

A CT and a RM was planned. CT demonstrated an inhomogeneous opacification of right sphenoidal sinus. The bone boundary was respected. RM showed a isointense opacification in T1 weighted images and a strong hypointense signal in T2 also called signal void. These finding allows to strongly suspect a mycosis of sphenoidal sinus. The sequences are quite typical for fungus ball. (Fig.2). The sphenoidal lesion was approached with a pure endoscopic transnasal direct approach. Into the sphenoidal sinus a inhomogeneous and dense material was found. The material was completely removed and three sample were collected. Sample one demonstrated the histological presence of hyphae. Sample two showed the growth of aspergillus fumigatus and the third sample did not demonstrate an invasion of the mucosa. In this case radiological findings and laboratory examination gave the same results. The case was a fungus ball. No antifungal therapy was given to the patient. The control after one month showed a good healing of the mucosa and a resolution of symptoms.

Case 2: Male 58 years. Previous diagnosis of non Hodgkin lymphoma treated with chemotherapy in a standard protocol. Since one year free of disease. When the patient was referred to ENT department from Haematological clinic the patient surfed from occipital headache and left retroorbital pain since one month and in last week a visual acuity decrease in left eye. CT scan demonstrated a left sphenoidal sinus opacification with a bone erosion of the planum and of the optic canal. The patient underwent to an urgent RM that showed a thin opacification of the walls of sphenoidal sinus with a hyperintense signal of the dura of planum and optic canal in T1 and hipointense and

absence of signal of those structures in T2. An endoscopic transethmoidal approach was planned in order to control orbital apex and optic nerve. A granulomatosis material invaded the sphenoid sinus. Three sample were collected. One with the content of the sphenoid sinus for histology, the second with the same
dura of planum to demonstrate deep invasion. Sample one demonstrated the histological presence of hyphae. Sample two showed the growth of aspergillus fumigatus and the third sample demonstrated an invasion of the mucosa submucosa and bone. The diagnosis was of chronic invasive mycosis. After surgery a long term systemic antifungal therapy
In this case radiological findings and laboratory examination gave the same results. The case was an invasive mycosis. The patient underwent to a long term antifungal therapy. The recovery of the mucosa was gained after two month and a complete release of symptoms after 8 month

Case 3: Fame 76 years. Diabetes not under medical control and hypertension. The patiet was referred from neurological department suffering from 1 week left ophthalmoplegia, retro orbital pain and left blindness. Ct scan demonstrated a left sphenoid sinus opacification with erosion of lateral, posterior and superior walls. RM showed a hyperinhyntense opacification in T1 weighted images and in T2 with a central strong hypointense signal suggestive for signal void with peripheral enhancement of the mucosa. An urgent endoscopic transnasal approach to sphenoid sinus was sufficient to access and clean sphenoid sinus. At the end of surgery was clearly demonstrated the erosion of bony walls e the pulsation of internal carotid artery was quite evident. The sample were collected as in previews cases. Sample one demonstrated the histological presence of hyphae. Sample two showed the growth of aspergillus fumigatus and the third sample did not demonstrated an invasion of the mucosa, submucosa and bone.
In this case radiological findings and laboratory examination gave the same results. The case was a fungus ball. No antifingal therapy was given to the patient. The control after two month showed a good healing of the mucosa and a resolution of left blindness, while ophtalmoplegya resolved after six month.

DISCUSSION

Accurate classification of FRS is important because the prognosis and treatment varies among FRS diagnoses. Although the clinical presentation or imaging

findings may provide diagnostic clues for each FRS category, the misdiagnosis or incorrect classification is rather frequent for fungal sinusitis and only tissue examination can provide accurate classification [3]. Fungal rhinosinusitis (FRS) comprises a spectrum of disease processes, which vary in clinical presentation, histologic appearances, and biological significance. FRS can be acute (aggressive; symptoms\ 30 days), subacute (symptoms 30–90 days), and chronic (indolent; symptoms [90 days) . The first attempt to classify fungal rhinosinusitis is due to Gora, who in 1965 divided the diseases into two categories according to the clinical course: invasive and non-invasive. In 1998 De Shazo proposed a classification of paranasal sinus mycosis based on for tissue invasive FRS based on the clinical condition, immune status, histopathology, and fungus infection[4]. More recently FRS terminology and pathologic classification has been further defined and reviewed by a group formed by the International Society for Human and Animal Mycology[2]: non-invasive sinonasal fungal diseases include saprophytic fungal infestation, fungal ball, and allergic fungal rhinosinusitis; the invasive forms of FRS include acute, chronic, and chronic granulomatous.

Saprophytic Fungal Infestation

This recently added additional category referred to a localized fungal colonization with nasal crusts formation. Is most commonly seen in patients with an intact immune system who have had prior sinus surgery or traumatic event. It results in in inflamed and ulcerated/crusted sinonasal mucosa with the presence of surface fungal infection without tissue invasion. The removal of the crusts provides full restoration[1,2,5] .

Fungus Ball

The fungal ball (FB) is an extramucosal, entangled mass of fungi usually associated with minimal mucosal inflammation. This nomenclature was favored by the International Society for Human and Animal Mycology Working Group over fungal mycetoma or aspergilloma. The etiopathology is still unclear. Some authors believe that fungal species deposited within the sinus via normal respiration and are inadequately cleared by mucociliary movement. Replication of organisms leads to growth of the fungal ball, phlogosis of surrounding mucosa, and ostial blockage[6,7].

Nicolai et al.[8] and Yoon et al.[9] reported the maxillary sinus the most commonly involved (respectively 84% and 88.7%), followed by the sphenoid sinus (14% and 9.9%) and, rarely, the ethmoid or frontal sinus.

Patients usually complain nonspecific symptoms typical of CRS, such as nasal congestion and facial pressure.

On computed tomography (CT) scan, the FB appears typically with hyperattenuated materials filling a single sinus, often with associated calcifications. Mucosa of the sinus is typically hypoattenuating and the surrounding bony walls may be expanded and thin or sclerotic and thickened. The fungal ball itself is typically hypointense on T1-weighted and T2-weighted images because of relative dehydration compared with normal mucosa and will fail to enhance with contrast, two features that differentiate it from a neoplastic process[10].

The diagnosis of a fungal ball is generally confirmed endoscopically during surgery when chalk-like concretions are found within the sinus. The surrounding sinus mucosa could appear inflamed.

Histologically, fungal balls are characterized by entangled masses of fungal organisms or masses of fungi embedded in fibrinous, necrotic exudate, with minimal mucosal inflammatory reaction. By definition, no tissue invasion or granulomatous reaction is present in the surrounding tissue[5]. Fungal cultures are often negative; however the most commonly isolated pathogen is Aspergillus sp.[11]

Surgical opening of the natural sinus ostium with evacuation of fungal debris is the treatment of choice. After removal of fungal hyphae, the sinus mucosa generally returns to a normal state of health and no additional treatment is usually necessary. Although tissue invasion is atypical of fungal balls, several reports of more aggressive cases exist[12,13].

In these rare instances, fungal balls have been associated with local tissue invasion, behaving in a fashion more characteristic of chronic invasive fungal sinusitis. This supports our thesis in which sinus mucosa should be examined for evidence of tissue invasion even in cases of obvious fungal ball.

Allergical Fungal Rhinosinusitis

Allergical fungal rhinosinusitis (AFRS) not considered to represent a true fungal infection but is rather a result of an inflammatory reaction toward fungi in the sinonasal tract. To diagnose AFRS, Bent and Kuhn[14] proposed five diagnostic criteria: type I hypersensitivity, nasal

polyposis, characteristic findings on CT scan, presence of fungi on direct microscopy or culture, and allergic mucin containing fungal elements without tissue invasion. Chakrabarti et al[1] classified the AFRS as a subgroup of eosinophilic fungal rhinosinusitis (EFRS) characterized by type 1 hypersensitivity to fungi, the presence of the so called allergic mucin with many eosinophils and the presence of noninvasive fungi with raised fungal specific IgE. From a clinical management standpoint, this distinction only matters insomuch as immunotherapy (subcutaneous or sublingual) could be considered in AFRS whereas it would not be indicated in EFRS[15].

AFRS symptoms are the same of CRS, including nasal congestion, facial pain/pressure, nasal discharge, and diminished olfaction. Patients typically have an intact immune system and often have a history of atopy, including allergic rhinitis and/or asthma.

The most well-documented fungal species in both AFRS is Aspergillus but other fungi, including Bipolaris, Alternaria, Cladosporium, and Curvularia species, may be found.

Most clinical series describe surgical therapy to remove polyps, open sinus ostia, and clear eosinophilic fungal mucin, followed by aggressive medical therapies. From the literature it appears that surgery in combination with other medical treatments such as oral and topical steroids or oral and topical antifungal leads to improved outcomes with better post-operative control of recurrence[16].

Acute Invasive Fungal Rhinosinusitis

Acute invasive FRS (AIFR) is a severe form of sinonasal fungal disease, which is characterized by rapid onset (less than 4 weeks' duration) and an aggressive clinical course, particularly if untreated. AIFRS is seen in immunocompromised patients: poorly controlled diabetes mellitus and prior chemotherapy, particularly in bone marrow transplant recipients, are most commonly predisposing factors[17]. Fungal invasion has also been described in individuals on chronic oral corticosteroids and those with human immunodeficiency virus. Aspergillus species, or members of the class zygomycetes are the most frequent etiological agents.

The clinical diagnosis of invasive fungal sinusitis may be delayed due to the lack of host response to infection. Diagnosis of IFS in the early stages, when the fungal load is less, is important to provide the

best overall outcome with respect to recovery and reducing morbidity. This can only be achieved by a fundamental understanding of patient risk-factors and appropriate clinical and exam findings. Fever, nasal symptoms of fullness or drainage, epistaxis, facial pain, and a daily examination of the orbital, sinus, and oral cavity is vital to optimize treatment outcomes in this incredibly morbid infection. When invasive infection is suspected, urgent consultation with otolaryngology and endoscopic examination and biopsy of suspicious areas is indicated[18].

CT scan in early stages may reveals unilateral mucosa thickening involving the nasal septum and floor and lateral wall of the nasal cavity. Retro-antral fat plane infiltration may be found in more advanced invasive forms[19]. Inflammatory spread transcranially or into the orbit may be subtle without obvious signs of bony erosion due to spread through vessels of intact sinus walls[20].

Imaging findings of bony invasion with extrasinus extension are used to be found in more fulminant and late processes.

MRI is more sensitive in the evaluation of patients with potential bone destruction and is a useful tool for pre-operative planning[19].

Grossly, the mucosa appears pale and necrotic due to vascular thrombosis from fungal invasion. Histologically, the mucosa shows infarction vascular thrombosis and usually scant inflammatory cells. Close review shows angioinvasion of fungal forms resulting in lumenal thrombosis[5].

Treatment of invasive fungal sinusitis includes surgical resection of necrotic tissues, systemic antifungal antibiotics, and reversal of immune dysfunction. The goal of surgical therapy is to remove all the necrotic, nonviable tissue[17]. The surgeon should continue the debridement until macroscopically healthy and bleeding tissue appears[21].

There are some controversies about the extent of the surgery, particularly with respect to disfiguring procedures such as maxillectomy and orbital exenteration. Intracranial extension of frank disease is rarely treated with direct surgical resection, because outcomes are notoriously poor[22,23].

Intravenous antifungal antibiotics are the mainstay of treatment, with liposomal amphotericin B the empiric drug of choice because of its activity against Zygomycetes and many *Aspergillus.* Post operative endovenous therapy should be adapted on the results of histopathology

and culture, avoiding the use of unappropriate antifungal agents.[17]

Treatments aimed at normalizing the immune system are critical to the success of comprehensive regimens.

Outcomes vary across case series with an overall mortality reported between the 18% (2004 Parikh et al) and the 41% (Chen et al), but failure to reverse immunosuppression and the presence of intracranial spread are consistently associated with increased mortality[24]

Chronic Invasive Fungal Rhinosinusitis

Chronic invasive FRS is a slowly destructive process that most commonly affects the ethmoid and sphenoid sinuses but may involve any paranasal sinus. The disease typically has a time course of >12 weeks. The majority of patients have underlying immune dysfunction, as in cases of poorly controlled diabetes mellitus, the receipt of long-term corticosteroids, or subtle immunologic abnormalities that co-exist with liver or renal disease, etc. However, cases have been reported in immunocompetent individuals[17].

Patients typically have been diagnosed with CRS and symptoms can initially be nonspecific. The progression of the disease and the fungal invasion into surrounding structure usually present with eye swelling and blindness. Radiographic imaging reveals a soft tissue mass within one or more of the paranasal sinuses and bony involvement may be apparent[10]. With extension to contiguous tissue, it is not uncommon for this condition to mimic malignancy given the tumor-like appearance on imaging.

Urgent surgery is necessary to confirm the diagnosis and to remove all involved tissue. Systemic antifungal treatment is also warranted and is dictated by the etiologic agent responsible for disease.

The diagnosis of chronic invasive fungal rhinosinusitis is confirmed at surgery when histopathology shows fungal hyphae infiltrating mucosa, blood vessels, or bone. Surrounding tissues often exhibit necrosis and a nonspecific inflammatory infiltrate, which differs from the noncaseating granulomas that characterize chronic granulomatous disease[25]. Fungal-specific cultures can grow a variety of species including dematiaceous molds (Bipolaris, Curvularia, and Alternaria), Aspergillus species, and Zygomycetes[24].

Overall morbidity and mortality appears to be better than acute invasive disease even if data from the literature are limited to small case series or case reports.

Granulomatous Invasive Fungal Rhinosinusitis

Most commonly found in countries such as India, Pakistan, and the Sudan, granulomatous invasive fungal rhinosinusitis is characterized by a time course of >12 weeks and characteristic histopathological findings. In fact, on histopathology, the presence of noncaseating granulomas confirms the diagnosis. Typically fungal hyphae may be found within Langerhans-type giant cells, sometimes with vasculitis, vascular proliferation, and perivascular fibrosis[25]. This unique pathology differentiates granulomatous invasive fungal disease from the more general chronic invasive fungal rhinosinusitis.

In literature the classification of paranasal sinus mycosis is nowadays clear. Clinical differentiation is quite simple in typical cases on the basis of the radiological findings and clinical history of the patient. In our reports, there are three cases of sphenoidal mycosis. In case one the clinical suspect of fungus ball was confirmed by histological and microbiological findings. In case two the three samples confirmed the suspect of invasive mycosis. The third case was not so clear in pre-surgical setting. Radiological findings showed a huge erosion of bony boundaries with the suspect of an invasive process. RM showed the typical signal void indicating the presence of fungus ball. Furthermore intracranial symptoms and the presence of immunosuppression related to not controlled diabetes and the age of patient were more suggestive for an invasive mycosis. The answer of the three samples oriented to fungus ball and no antifungal therapy was given to the patient with the resolution of symptoms.

CONCLUSION

In treatment of paranasal sinus mycosis is fundamental the correct diagnosis in order to plan postoperative medical therapy. In typical cases clinical setting and radiological results are sufficient to reach the diagnosis nevertheless in not typical cases the right diagnosis can be a challenge.

We believe that the systematic collection of the three samples can give fundamental and complemental information that can orient the correct postoperative treatment. Moreover, the collection and the analysis of three sample has a very low cost being feasible in all cases.

For this reason, we called this procedure the: “THE RULE OF THREE IN PARANASAL SINUS MYCOSOS”

REFERENCES

1. Chakrabarti A, Denning DW, Ferguson BJ, et al. Fungal rhinosinusitis: a categorization and definitional schema addressing current controversies. *Laryngoscope*. 2009;119(9):1809-1818.

2. Chakrabarti A, Das A, Panda NK. Controversies surrounding the categorization of fungal sinusitis. *Med Mycol*. 2009;47 Suppl 1:S299-308.

3. Granville L, Chirala M, Cernoch P, Ostrowski M, Truong LD. Fungal sinusitis: histologic spectrum and correlation with culture. *Hum Pathol*. 2004;35(4):474-481.

4. deShazo RD, Chapin K, Swain RE. Fungal sinusitis. *N Engl J Med*. 1997;337(4):254-259.

5. Montone KT. Pathology of Fungal Rhinosinusitis: A Review. *Head Neck Pathol*. 2016;10(1):40-46.

6. Grosjean P, Weber R. Fungus balls of the paranasal sinuses: a review. *Eur Arch Otorhinolaryngol*. 2007;264(5):461-470.

7. Stammberger H. Endoscopic surgery for mycotic and chronic recurring sinusitis. *Ann Otol Rhinol Laryngol Suppl*. 1985;119:1-11.

8. Nicolai P, Lombardi D, Tomenzoli D, et al. Fungus ball of the paranasal sinuses: experience in 160 patients treated with endoscopic surgery. *Laryngoscope*. 2009;119(11):2275-2279.

9. Yoon YH, Xu J, Park SK, Heo JH, Kim YM, Rha K-S. A retrospective analysis of 538 sinonasal fungus ball cases treated at a single tertiary medical center in Korea (1996-2015). *Int Forum Allergy Rhinol*. 2017;7(11):1070-1075.

10. Aribandi M, McCoy VA, Bazan C. Imaging features of invasive and noninvasive fungal sinusitis: a review. *Radiographics*. 2007;27(5):1283-1296.

11. Pagella F, Matti E, De Bernardi F, et al. Paranasal sinus fungus ball: diagnosis and management. *Mycoses*. 2007;50(6):451-456.

12. Robey AB, O'Brien EK, Richardson BE, Baker JJ, Poage DP, Leopold DA. The changing face of paranasal sinus fungus balls. *Ann Otol Rhinol Laryngol*. 2009;118(7):500-505.

13. Gungor A, Adusumilli V, Corey JP. Fungal sinusitis: progression of disease in immunosuppression--a case report. *Ear Nose Throat J*. 1998;77(3):207-210, 215.

14. Bent JP, Kuhn FA. Diagnosis of allergic fungal sinusitis. *Otolaryngol Head Neck Surg*. 1994;111(5):580-588.

15. Mabry RL, Mabry CS. Allergic fungal sinusitis: the role of immunotherapy. *Otolaryngol Clin North Am*. 2000;33(2):433-440.

16. Chang C, Gershwin ME, Thompson GR. Fungal disease of the nose and sinuses: an updated overview. *Curr Allergy Asthma Rep*. 2013;13(2):152-161.

17. Soler ZM, Schlosser RJ. The role of fungi in diseases of the nose and sinuses. *Am J Rhinol Allergy*. 2012;26(5):351-358.

18. DelGaudio JM, Clemson LA. An early detection protocol for invasive fungal sinusitis in neutropenic patients successfully reduces extent of disease at presentation and long term morbidity. *Laryngoscope*. 2009;119(1):180-183.

19. DelGaudio JM, Swain RE, Kingdom TT, Muller S, Hudgins PA. Computed tomographic findings in patients with invasive fungal sinusitis. *Arch Otolaryngol Head Neck Surg*. 2003;129(2):236-240.

20. Silverman CS, Mancuso AA. Periantral soft-tissue infiltration and its relevance to the early detection of invasive fungal sinusitis: CT and MR findings. *AJNR Am J Neuroradiol*. 1998;19(2):321-325.

21. Epstein VA, Kern RC. Invasive fungal sinusitis and complications of rhinosinusitis. *Otolaryngol Clin North Am*. 2008;41(3):497-524, viii.

22. Dhiwakar M, Thakar A, Bahadur S. Invasive sino-orbital aspergillosis: surgical decisions and dilemmas. *J Laryngol Otol*. 2003;117(4):280-285.

23. Jung S-H, Kim SW, Park CS, et al. Rhinocerebral Mucormycosis: consideration of prognostic factors and treatment modality. *Auris Nasus Larynx*. 2009;36(3):274-279.

24. Thompson GR, Patterson TF. Fungal disease of the nose and paranasal sinuses. *J Allergy Clin Immunol*. 2012;129(2):321-326.

25. Das A, Bal A, Chakrabarti A, Panda N, Joshi K. Spectrum of fungal rhinosinusitis; histopathologist's perspective. *Histopathology*. 2009;54(7):854-859.

FIGURES

Fig 1: Three samples are collected. 1 fungus for histological examination 2 fungus for microbiological examination 3 mucosa of the affected sinus for histological examination

Fig 2: CT scan show an opacification of right sphenoidal sinus with a central foreign body signal, bony boundaries are respected. MRI in T1 show an isointense opacification an a typical signal void in T2 sequences

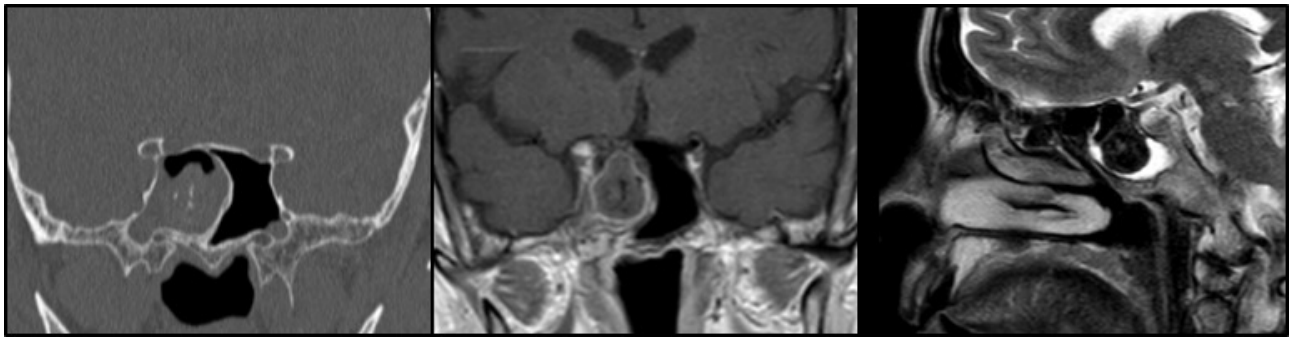

Fig 3: CT scan show an opacification of left sphenoidal sinus and an erosion of superior and supero lateral bony boundaries.

MRI in T1 show an hyperintense peripheral opacification of the superior wall of sphenoidal sinus and in T2 sequences a suspect signal void sign in the internal part of the opacification

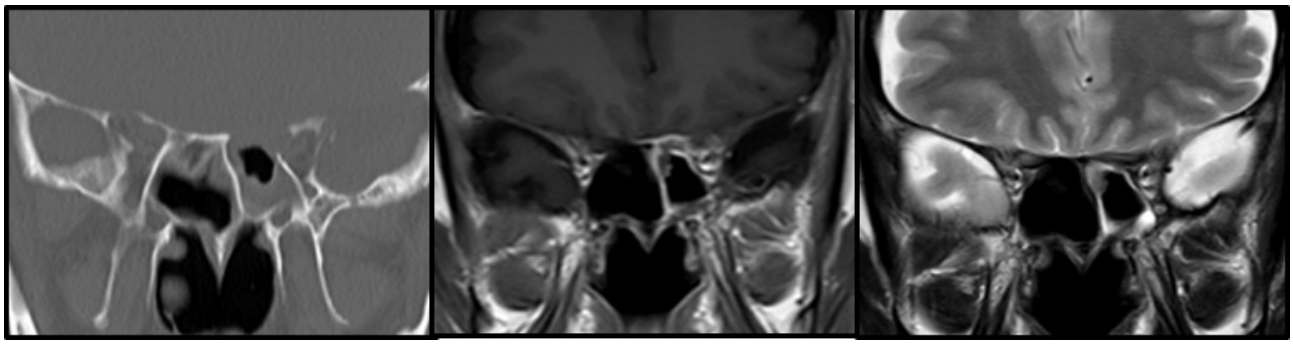

Fig 4: CT scan show an opacification of left sphenoidal sinus and an erosion of all bony boundaries. MRI in T1 show a peripheral isointense and central hyperintense opacification while in T2 sequences peripheral hyperintense and central isointense with a signal void sign in the central part.